

Management of Rectal Cancer



Michael A. Choti, MD MBA FACS
Departments of Surgery and Oncology
Johns Hopkins Medicine, Baltimore, Maryland, USA
Disclosures: NONE

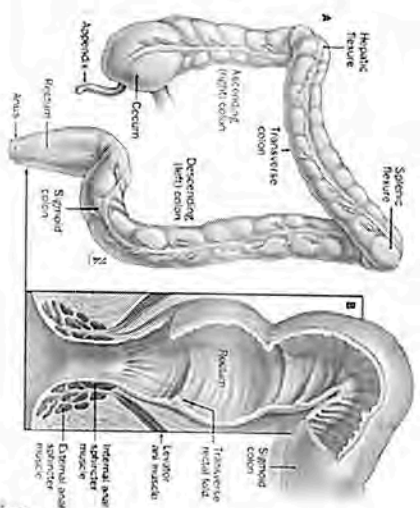
1

Rectal Cancer

- Defined as <12 cm from the anal verge by rigid proctoscopy.
- Distinct clinical management issues:
 - Increased local recurrence
 - Use of adjuvant radiation therapy
 - Use of neoadjuvant therapy and need to stage prior to surgery
 - Sphincter preservation
 - Concerns of urinary and sexual dysfunction

3

Anatomy of the Colon and Rectum



2

2

Goals of Rectal Cancer Surgery

- Improved local control
- Improved overall survival
- Maintaining quality of life
- Sphincter preservation
- Satisfactory bowel function
- Maintain genitourinary function
- Maintain sexual function


4

Sphincter Preservation for Rectal Cancer OUTLINE

1. What is the minimal distal margin bowel margin?
2. Importance of the circumferential margin and total mesorectal excision.
3. Impact of neoadjuvant therapy on sphincter preservation.
4. Reconstruction techniques & laparoscopy.
5. Role of diverting ileostomy.
6. Transanal local excision.

5

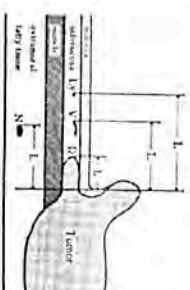
Adequacy of Even ≤ 1 -cm Distal Margin After Neoadjuvant Therapy?



Moore et al. Ann Surg Oncol 10:80 (2003)

7

Distal Intramural Spread of Rectal Cancer: End of the "5-cm Rule"

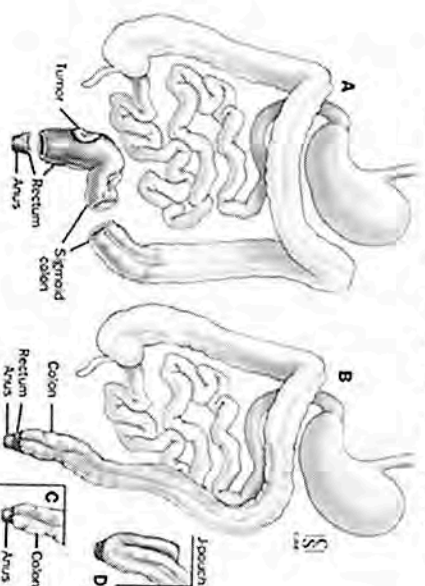


Stage	None	Distal Spread		
		<1cm	1-2cm	>2cm
I (n=150)	100%	0	0	0
II (n=162)	98.8%	1.2%	0	0
III (195)	90.2%	5.1%	2.1%	0

Shirouzu et al. Cancer 76:388 (1995)

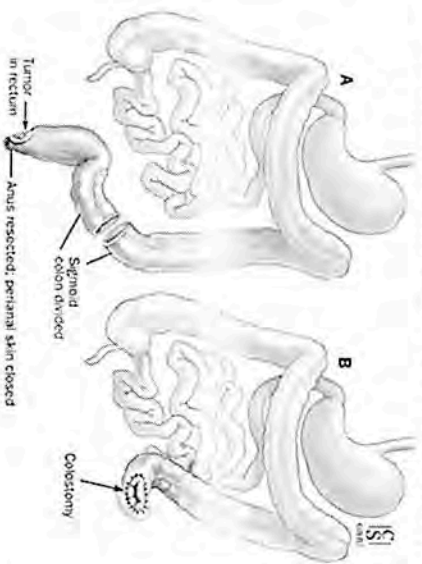
6

Low Anterior Resection (LAR)



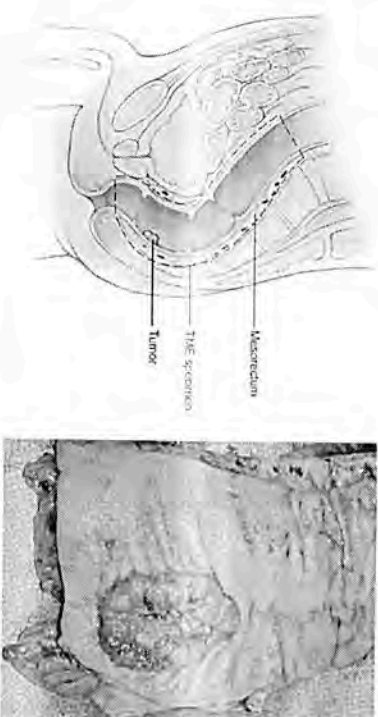
8

Abdominoperineal Resection (APR)



9

Total Mesorectal Excision



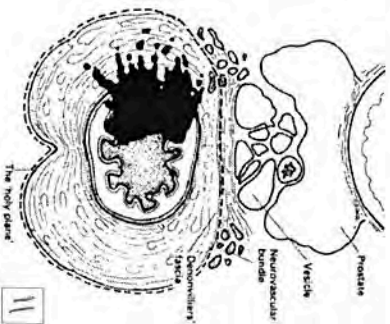
10

Importance of the Radial Margin

52 patients, 1983-1985
transabdominal resections
whole-mount pathologic evaluation
of radial resection margin
prospective follow-up


- Results:**
- 27% with positive radial margin
 - 12 of 14 with positive margins developed local pelvic recurrence (85%)
 - 1 of 38 with negative margins developed LR (3%)

Quirke P et al. Lancet 2:996, 1986



11

Pelvic Recurrence Rates Following Curative Resection for Rectal Cancer



12

Preoperative vs. Postoperative

POTENTIAL ADVANTAGES:

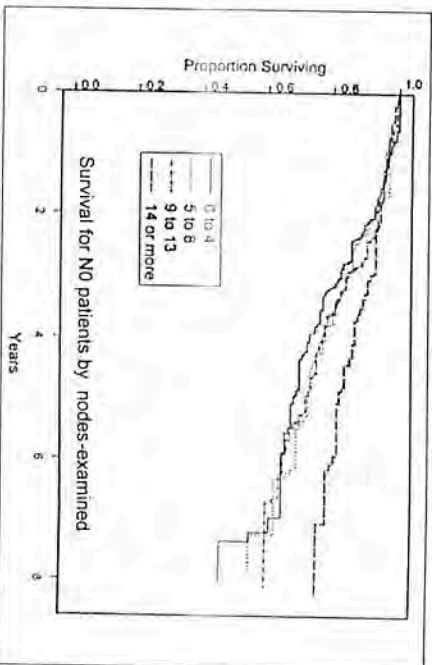
- Conversion to sphincter-preservation
- Less irradiated small bowel
- Improved late bowel function
- Earlier systemic therapy

POTENTIAL DISADVANTAGES:

- Staging uncertainty
- Overtreatment in some patients
- Delay in surgical therapy
- Increased operative complications?

13

Importance of an Adequate of Lymph Node Harvest



Tepper, J. E. et al. J Clin Oncol. 19:157-163 2001

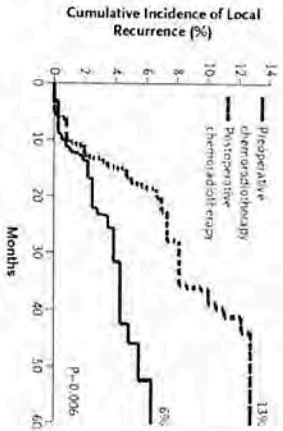
14

**Neoadjuvant Chemoradiation
German Rectal Cancer Study Group**

- Randomized trial
preop vs. postop CRT
- Conventional therapy

RESULTS:

- Improved local control
- Less toxicity
- No difference in survival



Sauer et al. NEJM 351:1731 (2004)

15

**Neoadjuvant Chemoradiation
German Rectal Cancer Study Group**

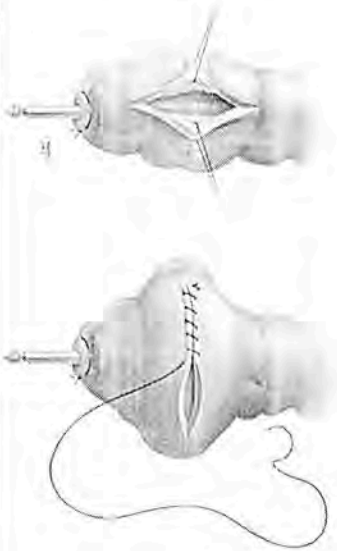
Table 4. Rates of Sphincter-Sparing Surgery in 194 Patients Determined by the Surgeon Before Randomization to Require Abdominoperineal Resection, According to Actual Treatment Given.

Variable	Preoperative Chemoradiotherapy (N=415)	Postoperative Chemoradiotherapy (N=384)	P Value
Abdominoperineal resection deemed necessary — no. (%)	116 (28)	78 (20)	0.004
Sphincter preserving surgery performed — no./total no. (%)	45/116 (39)	15/78 (19)	

Sauer et al. NEJM 351:1731 (2004)

16

Restorative Proctectomy Coloplasty



21

Local Excision: Selection Criteria

Lesion amenable to local excision

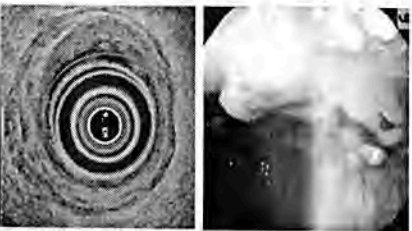
- Within reach of technique
- Full thickness
- Nonfragmented
- Negative margins

No adverse pathologic criteria

- High grade lesion
- Lymphovascular invasion
- Signet-ring cells
- Colloid histology

uT1 or ?uT2 on ERUS

No evidence of lymph node metastases
Patient not a candidate for LAR or APR



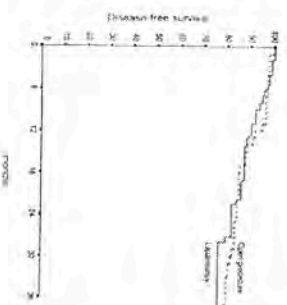
23

Laparoscopic Rectal Cancer Resection

144 patients
5.5 cm (range 1–12) from the anal verge
123 patients received preoperative radiotherapy

Results

Mortality & morbidity were 1% and 34%
Conversion was 14% (n = 20)
Intact mesorectum in 88% of the cases
Compared to matched open group, no difference in margin status, local recurrence or overall survival.



Bretagnol et al. *Surg Endosc* Jul 2005

22

Incidence of Positive Lymph Nodes by Pathologic Features

T-Stage	n	T1	T2	T3	T4
Nelson (1987)	76		20%	67%	
Morson (1979)	2084	11%	12%	58%	
Minsky (1989)	168	0%	28%	36%	53%
Brodsky (1992)	154	12%	22%		
Differentiation	n	Well	Mod	Poor	
Cohen (1980)	247	29%	32%	63%	
Nelson (1987)	76	38%	57%		
Minsky (1989)	168	0%	30%	50%	
Brodsky (1992)	154	0%	24%		

24

Outcomes Following Transanal Excision of Rectal Cancer

STUDY (yr)	N	FU (mo)	LR (%)	OS (%)
Chakravarti (99)	52	52	11 (T1) 62 (T2)	86
Steele (99)	110	48	7 (T1) 20 (T2)	87 (T1) 85 (T2)
Malignan (00)	108	53	17 (T1) 46 (T2)	69
Paty (02)	125	80	17 (T1) 26 (T2)	74 (T1) 72 (T2)
Madbouly (05)	52	55	29 (T1)	89 (T1)

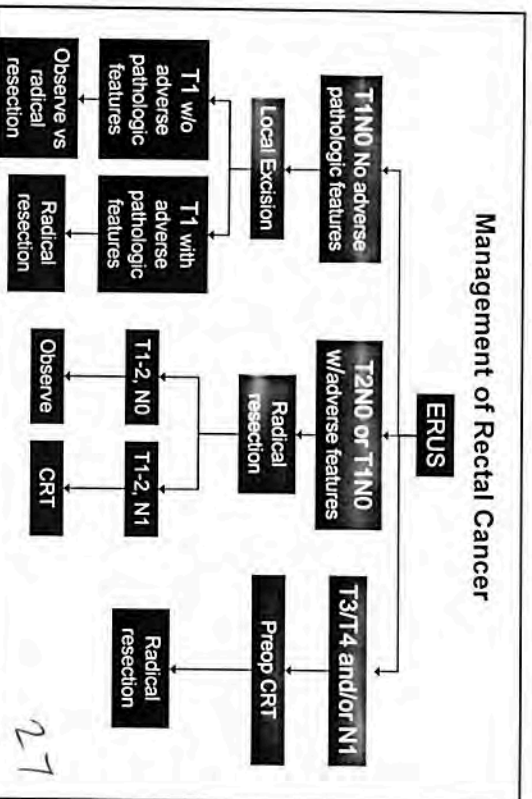
25

Local Excision for Rectal Carcinoma Followed by Radiation Therapy

Study	Local Control	Survival
Princess Margaret Hospital	76%	80% 6-yr median
Fox Chase Cancer Center	81%	75% 5-yr DFS
MSKCC	82%	79%
CALBG	98%	96% 2-yr

26

Management of Rectal Cancer



27

Temporary Ileostomy: When is it Necessary?

- Arguments in favor of ileostomy:
 - “protects” from anastomotic leaks
- Allows time for healing before bowel restoration
- Routine covering stoma has not been shown to be necessary
- Considered to be useful in patients at higher risk for anastomotic leak
 - Neoadjuvant radiotherapy
 - Coloanal anastomosis
 - Several comorbidities
- Take down is best performed after the completion of adjuvant therapy

28

Protective Defunctioning Stoma in Low Anterior Resection for Rectal Carcinoma

German prospective study (2000-2001)
881 of 2729 LAR pts received protecting ostomy

	Stoma	No stoma	p
Anastomotic leak	14.5%	14.2%	ns
Leak req. reoperation	3.6%	10.1%	<0.001
Mortality	0.9%	2.0%	0.037
Stomal closure complications:			
Colostomy	15.3%		
Ileostomy	22.4% (p=0.031)		

Gastinger et al. *Br J Surg* 92:1137 (2005)

29

Patient Case

A 55 yr. old college professor reports a 2 month history of narrow stools and occasional rectal bleeding. Colonoscopy demonstrates a mass 7 cm from anal verge and biopsy shows moderately differentiated adenocarcinoma.

30

Patient Case

Appropriate staging work-up includes:

- CT scan chest, abdomen & pelvis
- Endorectal ultrasound
- FDG-PET scan
- pelvic MRI

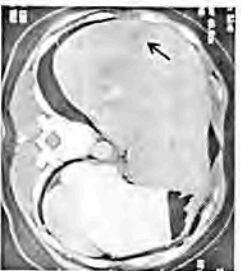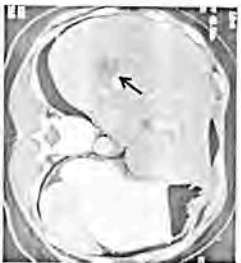31

Patient Case

The imaging studies show that the tumor invades into the bowel wall (T₂) and that there is a single 2-cm perirectal node. What management options best pertain to this case?

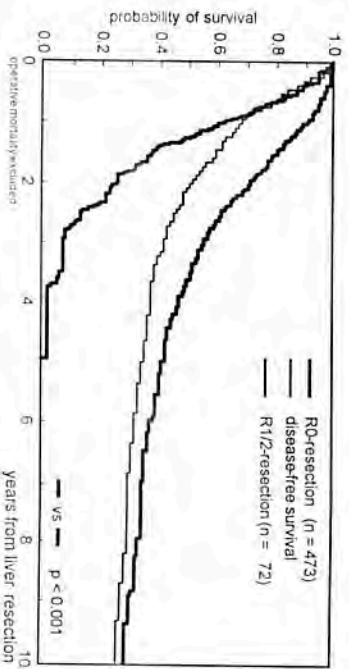
- Low anterior resection; postoperative adjuvant chemotherapy if nodes positive
- Neoadjuvant chemoradiotherapy using 5FU 300 mg/d CIV 5 days per week to coincide with radiotherapy, followed by surgery
- Neoadjuvant chemoradiotherapy using capecitabine 825 mg/m² po bid. continuously during RT, followed by surgery

32



33

Outcomes Following Hepatic Resection for Metastatic Colorectal Cancer



Scheele J et al Surg Oncol Clin N Amer 2003

34

Colorectal Cancer with Hepatic Metastases

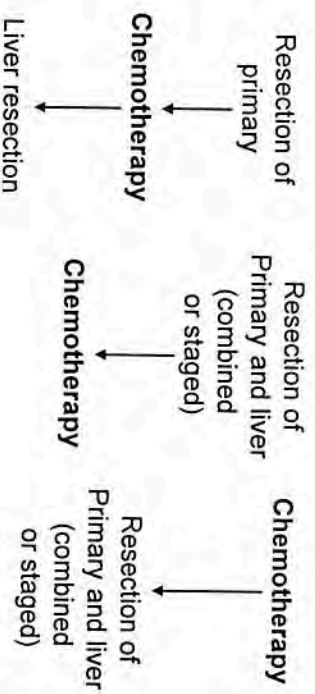
- Approximately 30% to 40% of patients will have liver-only metastases at time of recurrence
- Approximately 20% to 30% will have liver-only metastases on initial evaluation

25-30,000 patients with liver-only metastases

35

Ohlsson et al Acta Oncologica 42: 816-826, 2003
Weiss et al J Pathol 150: 195-203, 1986

Management Options for Synchronous Colorectal Cancer and Resectable Liver Metastases



36

Summary

1. Sphincter preservation and surgical technique
2. Importance of TME
3. Preoperative staging
4. Neoadjuvant therapy
5. Selected role of local excision for early disease
6. Management of Stage IV rectal cancer

37

CONCLUSIONS

1. Better understanding of the importance of circumferential vs distal margin and TME
2. Preoperative chemoradiation therapy
3. Refined surgical techniques
 - stapled low bowel attachment
 - coloanal reconstruction
 - J-pouch and coloplasty
 - local excision in selected cases

38